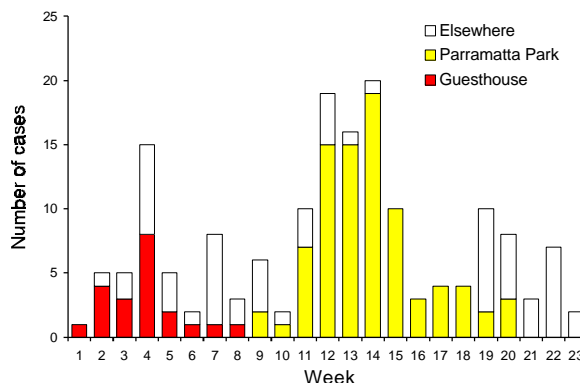


only had mild haemorrhage) and one case of dengue encephalopathy (a male in his 20's who collapsed at work, had several seizures and became increasingly unrousable). Clearly those affected in this outbreak are more ill than those affected in last year's dengue 2 outbreak in the Torres Strait.

The outbreak seems to be slowing down, and we hope it will soon be over. That the number of cases has been held down to less than 22 so far is a credit to the hard work of the Entomological and Environmental Health staff of TPHU and the Cairns City Council.

**Figure 1. Notifications of dengue 3, from December 1997, Cairns, by location and week**



## A case of infant botulism in South Australia

Rosalind Holland, Communicable Disease Control Branch, South Australian Department of Human Services, PO Box 6, Rundle Mall, South Australia 5000

This report documents the first case of infant botulism recorded in South Australia since 1990.

On 25 May 1998 a case of infant botulism was notified to the Communicable Disease Control Branch. The 6 month old female, from a northern country area of South Australia, was admitted to hospital with paralysis and was diagnosed initially on clinical grounds. She had decreased spontaneous movement, reduced anti-gravity movements, no head movements, and gag and cough reflexes were absent. She was intubated, ventilated and given general supportive treatment.

The baby had become unwell the day before with lethargy and difficulty feeding, and was described by the mother as 'being uncomfortable'. The mother also reported constipation occurring some days before. The diagnosis was confirmed serologically and by tests in mice.

The baby was breast fed on demand and solid foods had been introduced over the previous 6 weeks. Foods consumed included commercially prepared apricot and rice, pear, mango and apple, and pumpkin either from jars or tins, sweet biscuits and a baby rice cereal. The infant also ate home prepared chicken and vegetable, and toast with Vegemite. No honey or corn syrup was consumed. The family has a dog and keeps chickens although the baby did not have contact with the animals.

Infant botulism results from spore ingestion and subsequent vegetative growth, and in-vivo toxin production in the intestine by *Clostridium botulinum*. The syndrome affects infants almost exclusively, but can affect adults who have altered gastro-intestinal anatomy and microflora. The

illness typically begins with constipation followed by lethargy, listlessness, poor feeding, ptosis, difficulty swallowing, loss of head control, hypotonic extending to generalised weakness (the 'floppy baby') and, in some cases respiratory insufficiency and arrest.

There are many sources of spores, including foods and dust. Honey and corn syrup have been implicated in infant botulism. Environment and food sampling in isolated cases, such as the one reported here, is unrewarding because of the ubiquitous nature of the organism.

### References

Benenson, Abram S, editor. *Control of Communicable Diseases Manual*. Sixteenth Edition. Washington: American Public Health Association, 1995.

### Editorial note

This is the first notification of a case infant botulism in Australia since botulism became a nationally notified disease in 1992. Infant botulism generally occurs between the ages of 2 weeks and 1 year, with 94% of cases occurring at or before the age of 6 months. Clinical severity can range from mild illness with gradual onset to severe respiratory insufficiency and death. Case fatality rates in countries with good paediatric intensive care units are less than 1%. Excretion of *C. botulinum* toxin and organisms can occur in the faeces for extended periods (weeks to months) but no instance of secondary person-to-person transmission has been documented.

An antitoxin is available but is not recommended in the treatment of infant botulism.